

## A Prospective Genetic Evaluation of Familial Dilated Cardiomyopathy in the Doberman Pinscher

Kathryn M. Meurs, Philip R. Fox, Michelle Norgard, Alan W. Spier, Allison Lamb, Shianne L. Koplitz, and Ryan D. Baumwart

**Background:** The Doberman Pinscher is one of the most common breeds of dogs to develop dilated cardiomyopathy (DCM), a primary heart muscle disorder characterized by myocardial dysfunction, cardiac arrhythmias, and congestive heart failure. In the Doberman Pinscher, the disease is typically adult onset, and a familial etiology has been suggested.

**Hypothesis:** DCM in the Doberman Pinscher, is a familial disease linked to a specific genetic marker.

**Animals:** The study comprised an extended family of Doberman Pinschers with a history of DCM.

**Methods:** Participating dogs were prospectively evaluated over an 8-year period. Phenotype of participating dogs was determined by annual echocardiography and ambulatory electrocardiography, and the pedigree was evaluated to determine a specific mode of inheritance. Three hundred seventy-two microsatellite markers were selected and genotyped to cover the 38 autosomal chromosomes. Phenotyping, genotyping, and pedigree information was entered into a database, and parametric, 2-point analysis was performed. Markers were considered to be linked to the development of DCM if the logarithm of odds LOD score was  $\geq 3.0$ .

**Results:** An autosomal dominant mode of inheritance was defined by the appearance of the disease in multiple generations, equal gender representation ( $P = .973$ ) and male-to-male transmission. A maximum LOD score of 1.31 was obtained for 1 marker on chromosome 20, a score not high enough to be associated with DCM.

**Conclusion:** DCM in the Doberman Pinscher is a familial disease inherited as an autosomal dominant trait. The causative gene(s) responsible for this condition remain unresolved. Association studies by means of array technology may provide new insights into gene identification.

**Key words:** Dilated cardiomyopathy; Doberman Pinscher; Familial; Genetic; Linkage.

The Doberman Pinscher is one of the most common breeds of dogs to develop dilated cardiomyopathy (DCM), a primary heart muscle disorder characterized by myocardial dysfunction, cardiac arrhythmias, and congestive heart failure.<sup>1–3</sup> In the Doberman Pinscher, the disease is adult onset (median of 7.5 years at diagnosis) and appears particularly aggressive.<sup>4,5</sup> There is no definitive treatment and therapy is at best palliative.<sup>6</sup> Previous studies have suggested a familial etiology.<sup>7,8</sup> Unfortunately, affected dogs typically do not develop the disease until they are beyond the age of selection for breeding purposes. Thus, a dog may produce several litters before it develops any clinical signs and is determined to be affected. Early identification of affected animals would allow for exclusion of these dogs from breeding programs and would allow early medical intervention, although it is not yet known if this would have a significant impact on survival. There is significant interest in the identification of the causative

gene for Doberman Pinscher DCM and the development of a DNA-based screening test.

A similar form of cardiomyopathy exists in human beings and is inherited in at least 20–40% of the cases.<sup>9</sup> Familial DCM in human beings can be inherited in an autosomal dominant, X-linked, autosomal recessive or mitochondrial pattern, but the autosomal dominant form is reported most frequently. Although in many of these cases the specific genetic mutation has not been identified, causative mutations have been identified in 24 genes, including actin, dystrophin and desmin among others.<sup>9–13</sup> The majority of these genes encode for cytoskeletal proteins that have important structural functions in the cell including maintaining structural integrity, preserving cell shape, organizing the contractile apparatus, and enabling the cell to withstand mechanical stress.<sup>14</sup> It has been suggested that an abnormality of a cytoskeletal protein may be a common factor in the development of DCM and that without the structural support provided by these proteins, a dilated, dysfunctional heart develops.<sup>12</sup> Mutations within different genes, or within different areas of the gene may result in different clinical manifestations and survival times.

Information about the human form of familial DCM can provide insight into the Doberman Pinscher disease. A candidate gene approach can be pursued by evaluating the genes known to cause the disease in human beings as candidates for the Doberman Pinscher disease. However, because there are now 24 different genes known to cause familial DCM in human beings, the candidate gene approach would be quite time consuming.<sup>10</sup> Narrowing down the list of candidate genes might be accomplished by determining the mode of inheritance. This would allow the exclusion of certain genes associated with specific modes of inheritance. In addition, the list could be more focused by performing

---

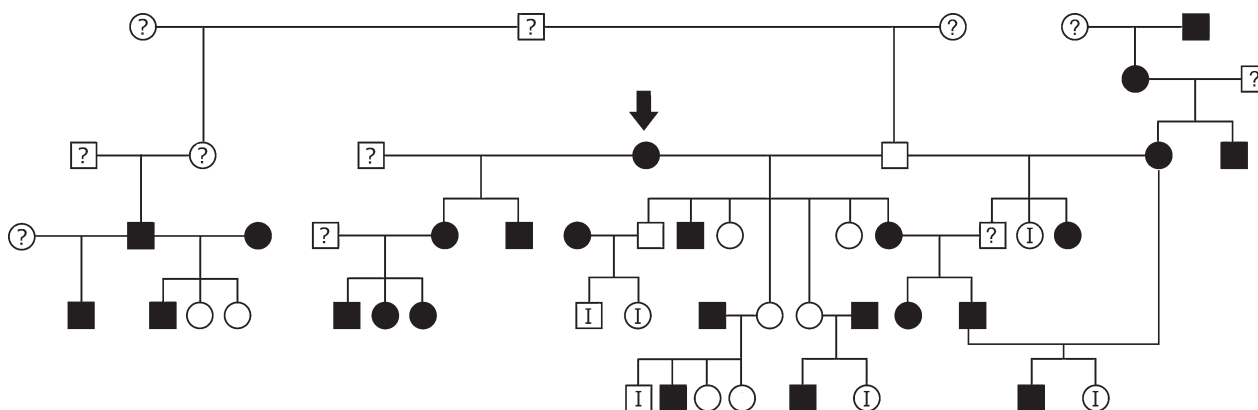
From the Department of Veterinary Clinical Sciences, College of Veterinary Medicine, Washington State University, Pullman, WA (Meurs, Norgard); and the Animal Medical Center, New York, NY (Fox); and the Department of Veterinary Clinical Sciences, College of Veterinary Medicine, The Ohio State University, Columbus, OH (Spier, Lamb, Koplitz, Baumwart). Dr Spier is presently affiliated with Florida Veterinary Specialists, Tampa, FL. Dr Koplitz is presently affiliated with Wisconsin Veterinary Referral Center, Waukesha, WI.

Reprint requests: Dr Kathryn Meurs, Department of Veterinary Clinical Sciences, College of Veterinary Medicine, Washington State University, Pullman, WA 99164; e-mail: Meurs@vetmed.wsu.edu.

Submitted January 25, 2007; Revised April 10, 2007; Accepted April 23, 2007.

Copyright © 2007 by the American College of Veterinary Internal Medicine

0891-6640/07/2105-0019/\$3.00/0



**Fig 1.** Pedigree from a Doberman Pinscher family with dilated cardiomyopathy and an autosomal dominant mode of inheritance. Mode of inheritance was determined by the appearance of the disease in multiple generations, equal gender representation ( $P = .973$  (affected F<sup>11</sup> and affected M<sup>14</sup>) and evidence of male-to-male transmission. Finally, the mating of 2 affected animals produced unaffected dogs. The proband is indicated by an arrow. Circles represent female dogs; squares represent male dogs. Solid black symbols represent affected animals; an I in the symbol represents dogs classified as indeterminate; solid white symbols represent unaffected animals; a question mark in the symbol represents animals not available for evaluation.

linkage analysis to identify a statistical relationship between the disease and specific genetic regions or a gene. The objectives of this study were to prospectively evaluate an extended family of Doberman Pinschers with DCM to determine a pattern of inheritance and to perform genetic linkage analysis to identify a region of the canine genome that is linked to the disease. Ultimately, the region linked to the disease could contain important cardiac genes that could be evaluated as possible causes of DCM.

## Materials and Methods

This study was conducted in accordance with the Position of the American Heart Association on Research Animal Use and under the guidelines of the Animal Care and Use Committee of the Ohio State University.

### Phenotypic Classification and Pedigree Analysis

A family of Doberman Pinschers with a history of DCM was prospectively evaluated over an 8-year period after the initial proband was diagnosed (Fig 1). Forty-one dogs in 4 generations were evaluated annually with a physical examination, 24-hour ambulatory electrocardiogram, an echocardiogram (2D and M-mode) and a postmortem cardiovascular evaluation when possible, to classify the phenotype. The ambulatory electrocardiogram was recorded with a 3-channel transthoracic ambulatory electrocardiographic (AECG) system<sup>a</sup> by a technique previously described.<sup>15</sup> The total number of ventricular premature complexes (VPCs) was tabulated. Echocardiographic examination was performed by transthoracic echocardiography with a GE Vivid 7 echocardiographic system<sup>b</sup> and included both 2D and M-mode evaluation. Left ventricular internal dimensions during systole (LVISD), diastole (LVIDD), and fractional shortening (FS%) were determined from the M-mode study at the left ventricular level. The examinations were conducted without sedation by means of standard clinical techniques described for the dog.<sup>16</sup>

Participating dogs were classified as affected, unaffected, or indeterminate based on the following criteria. An affected status was assigned to dogs that had echocardiographic measurements of an LVIDD >4.6 cm or an LVISD >3.8 with an FS% <25%.<sup>17</sup> Dogs were classified as unaffected if they reached the age of 9 with

a ventricular size within normal limits for their size and had annual AECG recordings of less than 50 VPCs/24 hours.<sup>18,19</sup> Dogs were classified as indeterminate if their ventricular dimensions exceeded 4.6 or 3.8, they had >50 VPCs/24 hours but their FS% was still above 25%, or both, or if the FS% was <25% but the ventricular dimensions were within normal limits. In addition, dogs with normal echocardiograms and AECG evaluations were classified as indeterminate until they were at least 9 years of age. Given the adult-onset nature of the disease, all indeterminate or unaffected dogs were evaluated annually. When possible, dogs that died prematurely during the study were subjected to postmortem evaluation.

### Pathologic Description

Hearts were weighed and fixed in 10% phosphate-buffered formalin. Chamber sizes were assessed as described.<sup>20</sup> Transverse, 5-mm sections were obtained perpendicular to the longitudinal axis of the ventricular chambers at the level of chordae tendineae and toward the apex at the level of the left ventricular (LV) papillary muscles. Full-thickness tissue blocks were embedded in paraffin, sectioned at a thickness of 5  $\mu$ m, placed on glass tissue slides, processed by routine histologic methods, stained with hematoxylin and eosin and Masson's trichrome stains, and evaluated by light microscopy. Lesions were described by means of nomenclature and observations reported for DCM in Doberman Pinschers.<sup>21</sup>

### Pedigree Evaluation

The pedigree was evaluated to determine the familial nature of the disease and to determine a specific mode of inheritance as described.<sup>22</sup>

### Linkage Analysis

Ten milliliters of blood were collected from each dog, and DNA was extracted from peripheral lymphocytes as previously described.<sup>23</sup> With the phenotypic information from the family, simulated linkage analysis by Slink software<sup>c</sup> with assumptions of a fully penetrant autosomal dominant inheritance with 100 replications was performed. An average logarithm of odds (LOD) score of 1.5 with a maximum score of 4.18 was obtained.

Microsatellite markers were selected from the 38 autosomes to provide approximately 9 megabase (Mb) coverage and amplified as

**Table 1.** Phenotypic information for a family of Doberman Pinschers with dilated cardiomyopathy.<sup>a</sup>

	DCM FS%	I FS%	U FS%	DCM LVIDD	I LVIDD	U LVIDD	DCM LVIDS	I LVIDS	U LVIDS	DCM VPC	I VPC	U VPC
Mean	22.7	31.5	30.8	4.9	4.7	4.1	3.8	3.3	2.8	2602	64	19
SD	2.2	5.6	3.3	0.47	0.71	0.39	0.45	0.65	0.36	6065	124	21

DCM, dilated cardiomyopathy; I, indeterminate group; U, unaffected group; FS%, fractional shortening; LVIDD, left ventricular internal dimensions during diastole; LVIDS, left ventricular internal dimensions during systole; VPC, ventricular premature complex; SD, standard deviation.

<sup>a</sup> A significant difference was observed for the echocardiographic (FS%, LVIDD, LVIDS) parameters between the affected (DCM) and unaffected (U) (FS%  $P < .001$ , LVIDD  $P < .01$ , LVIDS  $P < .001$ ) and DCM and indeterminate (I) groups (FS%  $P < .001$ ) but not between the I and U groups. A significant difference was observed for VPC number between the DCM and U group ( $P = .007$ ) but not the DCM and I, or U and I.

described.<sup>24,25</sup> After performing polymerase chain reaction (PCR), the samples were electrophoresed on an ABI Prism 377 Sequencer.<sup>d</sup>

Allele sizes were determined by Genotyper software<sup>d</sup> and genotypes were entered into a database.

### Statistical Analysis

Differences for age and for echocardiographic and AECG findings between the groups were determined by 1-way analysis of variance (ANOVA) with an alpha of 0.05. Phenotyping data, genotyping data, and pedigree information were entered into a database, and parametric, 2-point analysis was performed with the assumption of an autosomal dominant mode of inheritance. The LOD scores between DCM and each marker were tested by Mlink as described with a recombination value of 0.1.<sup>26</sup> Markers were considered to be linked if the LOD score was  $\geq 3.0$ .

### Results

Based on the criteria listed above, 10 dogs (3 female intact [F], 5 female spayed [FS], and 2 male intact [M]) dogs were classified as unaffected; 6 (2 F, 2 FS, 1 M, and 1 male castrate [MC]) were classified as indeterminate; and 25 (7 F, 4 FS, 11 M, and 3 MC) were classified as affected. A significant difference was noted between the age of the 3 groups ( $P = .01$ ). The mean age,  $\pm$  standard deviation of the affected group was 8 years  $\pm$  2, the indeterminate group was 6  $\pm$  2, and the unaffected group was 10 years  $\pm$  1. A significant difference was observed for the echocardiographic (FS%, LVIDD, and LVIDS) parameters between the affected and unaffected (FS%  $P < .001$ , LVIDD  $P < .01$ , LVIDS  $P < .001$ ), and affected and indeterminate groups (FS%  $P < .001$ ) but not between the indeterminate and unaffected groups. A significant difference was observed for VPC number between the affected and unaffected groups ( $P = .007$ ) but not the affected and indeterminate or unaffected and indeterminate groups (Table 1).

Pathologic evaluation of the heart was performed in 6 of the affected dogs (2 MC, 2 M, 2 F). Causes of death included euthanasia due to progressive heart failure ( $n = 5$ ) and sudden death ( $n = 1$ ). Moderate to severe dilation of all 4 cardiac chambers were judged to be present by inspection in 5 of the 6. The additional dog with DCM had mild to moderate dilation of all 4 chambers. Heart weights varied from 307 to 371 g (mean, 325.3 g; standard deviation [SD], 23.1 g). Heart weight:body weight ratios varied from .0008 to .0009 (mean, .0008;

SD, .0005) (normal .0007  $\pm$  .0003 g/kg).<sup>27</sup> Histologic lesions were observed in all hearts and comprised a typical complex localized to the mid mural region of the LV free wall. This lesion complex was characterized predominantly by marked myofiber degeneration and atrophy, with myocardial replacement by thick bands of collagen fibers and was accompanied by aggregates of fat. In the interventricular septum, mild to moderate interstitial fibrosis was present in all dogs. Components of multifocal myocytolysis, myocardial necrosis, and multifocal, mild fibrosis were also present in 1 or more atrial and ventricular walls in all dogs. In addition, chronic, degenerative myxomatous changes were observed in the left and right atrioventricular valve leaflets in all dogs.

An autosomal dominant mode of inheritance was defined by the appearance of the disease in multiple generations, equal gender representation ( $P = .973$  (affected F<sup>11</sup> and affected M<sup>14</sup>) and evidence of male-to-male transmission. Finally, the mating of 2 affected animals produced unaffected dogs (Fig 1).<sup>22</sup>

Genotyping was performed for 372 microsatellite markers covering the 38 autosomes. Seventy-two of the markers were nonpolymorphic in this family. At least 5 informative markers were evaluated on every autosomal chromosome with an average of 8 per chromosome (range, 5–14). A maximum LOD score of 1.31 was obtained for marker 3109 on canine chromosome 20; however, flanking markers for 3109 had scores  $< 1.0$ .

### Discussion

The results of this study indicate that DCM in this family of Doberman Pinschers is a familial disease inherited as an autosomal dominant trait. These findings support what had been previously suggested in a small retrospective study of Doberman Pinscher DCM.<sup>7</sup> The familial nature of the disease in this breed and the identification of an autosomal dominant form of inheritance is also consistent with the most common mode of inheritance of DCM in human beings. In addition, it supports the observation that genetic disease may occur with high frequency in populations with closed gene pools and in which breeding of close relatives is used to propagate desired traits.<sup>28,29</sup> Breeds established from a small number of founders and

expanded rapidly are thought to be particularly susceptible.<sup>30</sup> The Doberman Pinscher is a relatively new breed of dog with records suggesting that the breed was established in the late 1890s in Germany.<sup>31</sup> Importation of dogs to the United States became popular after World War II and by 1950, one half of the Doberman Pinscher American Kennel Club champions were the direct descendents of 7 closely related Doberman Pinschers imported from Germany in 1941. Three of these dogs are reported to have died of cardiac disease. The proband in the family presented here is a direct descendent of 1 of these dogs. Although it is possible that different families of Doberman Pinschers with DCM will demonstrate a different mode of inheritance, this would seem unlikely given that the Doberman Pinscher is a pure breed dog with a closed gene pool at least in registered dogs. Therefore, it is more reasonable to assume that most of the affected dogs in this breed would share a pattern of inheritance.

The determination of the affected and unaffected phenotype in the present study was challenging due to the adult onset nature of DCM in this breed.<sup>4</sup> Diagnostic criteria were based on previous studies that suggested that both echocardiographic and ambulatory electrocardiographic evaluation were important for detection of different stages of the disease.<sup>17,18</sup> All dogs in the present study were prospectively evaluated on an annual basis by both echocardiography and ambulatory electrocardiography. Some dogs died before reaching the age of disease onset and were unavailable for post-mortem evaluation. These dogs were classified as indeterminate. The number of dogs whose clinical status could not be definitively defined is a limitation of this study as well as others that study adult onset diseases in natural animal populations. Although careful attention was paid to reevaluation of all dogs on an annual basis, it is impossible to control premature loss of animals as a result of death from other causes.

Pathologic findings in the hearts of the affected dogs were consistent with cardiac lesions reported in Doberman Pinscher with DCM.<sup>2,21</sup> The affected dogs that underwent pathologic evaluation were relatively old for this breed, and the presence of myxomatous changes in their atrioventricular valves is in keeping with the development of these lesions in elderly dogs.<sup>32</sup>

There is substantial interest in the development of a genetic test for familial canine DCM to allow for early detection of affected animals. A linkage analysis approach was previously performed in a family of Newfoundland dogs with DCM.<sup>33</sup> It is regrettable that statistical analysis did not identify a chromosomal region that was statistically linked to DCM in that Newfoundland family or the Doberman Pinscher family presented here. A simulated linkage analysis program with assumptions of a fully penetrant autosomal dominant inheritance with 100 replications was performed in this study to predict the likelihood of successful linkage analysis. This predicted an average LOD score of 1.5 with a maximum score of 4.18. Although this analysis was used as a starting point for the study, it has some limitations. The penetrance of

DCM in the Doberman Pinscher is unknown, but it is incomplete in human beings.<sup>34</sup> Therefore, the calculations in this study may have been a bit optimistic. The high LOD score of 1.31 identified here was close to the average predicted by the simulation but we did not come close to the maximum predicted score. In the study performed here we completed the analysis after evaluating just under 400 markers over the 38 autosomal chromosomes. Almost 20% of the markers were non-polymorphic for this family. A higher LOD score might have been identified if additional markers were evaluated and if the family was more powerful (larger number of animals, fewer animals of indeterminate status).

However, the identification of an autosomal dominant mode of inheritance for DCM in the Doberman Pinscher supports further investigation of candidate genes that have been associated with the autosomal dominant pattern in human beings. Causative mutations for familial DCM in human beings have now been identified in 24 different genes but the autosomal dominant form of it has only been linked to 16 different loci and several different genes including actin, desmin, phospholamban, alpha-sarcoglycan, beta-sarcoglycan, troponin T, beta myosin heavy chain and alpha tropomyosin.<sup>34</sup> Evaluation of the desmin and delta sarcoglycan genes by typing of adjacent genetic markers in affected and unaffected Doberman Pinschers did not support a role for these genes in Doberman Pinscher DCM.<sup>35,36</sup> In addition, the promoter and coding regions of the phospholamban gene and coding region of the actin gene have been excluded by direct sequencing in affected and unaffected dogs.<sup>37,38</sup>

In conclusion we have demonstrated that DCM in the Doberman Pinscher dogs is a familial disease inherited as an autosomal dominant trait. Due to the autosomal dominant nature, genes that have been found to be involved in the development of X-linked DCM may be de-emphasized in future studies. A genome wide scan with microsatellite markers of Doberman Pinscher DCM has limitations due to the adult onset nature of this disease and the likely incomplete penetrance. In the future, association studies with single nucleotide polymorphism array technology may prove to be more valuable. Further investigations remain necessary to identify the causative gene(s) responsible for this condition.

---

## Footnotes

<sup>a</sup> Delmar Medical Systems, Irvine, CA

<sup>b</sup> General Electric, Fairfield, CT

<sup>c</sup> SLINK, New York, NY

<sup>d</sup> Applied Biosystems, Foster City, CA

---

## Acknowledgments

Funding for this study was graciously supplied by the AKC-Canine Health Foundation and the Morris Animal Foundation.

## References

- Buchanan JW. Prevalence of cardiovascular disorders. In: Fox PR, Sisson DD, Moise NS, eds. *Textbook of Canine and Feline Cardiology*, 2nd ed. Philadelphia, PA: WB Saunders; 1999:457–470.
- Tidholm A, Jonsson L. A retrospective study of canine dilated cardiomyopathy (189 cases). *J Am Anim Hosp Assoc* 1997;33:544–550.
- Monnet E, Orton EC, Salman M, et al. Idiopathic dilated cardiomyopathy in dogs: Survival and prognostic indicators. *J Vet Intern Med* 1995;9:2–7.
- Calvert CA, Pickus CW, Jacobs GJ, et al. Signalment, survival, and prognostic factors in Doberman Pinschers with end-stage cardiomyopathy. *J Vet Intern Med* 1997;11:323–326.
- Petric AD, Stabej P, Zemva A. Dilated cardiomyopathy in Doberman Pinschers: Survival, causes of death and a pedigree review in a related line. *J Vet Cardiol* 2002;4:17–24.
- Luis Fuentes V, Corcoran B, French A, et al. A double-blind, randomized, placebo-controlled study of pimobendan in dogs with dilated cardiomyopathy. *J Vet Intern Med* 2002;16:255–261.
- Hammer TA, Venta PJ, Eyster GE. The genetic basis of dilated cardiomyopathy in Doberman Pinschers. *Anim Genet* 1996;27:101–119.
- Calvert CA. Dilated congestive cardiomyopathy in Doberman Pinschers. *Compend Contin Educ Prac Vet* 1986;8:417–430.
- Fatkin D, Graham RM. Molecular mechanisms of inherited cardiomyopathies. *Physiol Rev* 2002;82:945–980.
- Osterziel KJ, Habfeld S, Geier C, et al. Familiäre dilatative Kardiomyopathie. *Herz* 2005;30:529–534.
- Olson TM, Michels VV, Thibodeau SN, et al. Actin mutations in dilated cardiomyopathy, a heritable form of heart failure. *Science* 1998;280:750–752.
- Towbin JA. The role of cytoskeletal proteins in cardiomyopathies. *Curr Opin Cell Biol* 1998;10:131–139.
- Towbin JA, Hejtmanic F, Brink P. X-linked dilated cardiomyopathy: Molecular genetic evidence of linkage to the Duchenne muscular dystrophy (dystrophin) gene at the Xp21 locus. *Circulation* 1993;87:1854–1865.
- Maeda M, Holder E, Lowes B, et al. Dilated cardiomyopathy associated with deficiency of the cytoskeletal protein metavinculin. *Circulation* 1997;95:17–20.
- Meurs KM, Spier AW, Wright NA, et al. Use of ambulatory electrocardiography for detection of ventricular premature complexes in healthy dogs. *J Am Vet Med Assoc* 2001;218:1291–1292.
- Thomas WP, Gaber CE, Jacobs GJ. Recommendations for standards in transthoracic two-dimensional echocardiography in the dog and cat. *J Vet Intern Med* 1993;7:247–252.
- O'Grady MR, Horne R. Occult dilated cardiomyopathy in the Doberman Pinscher. *Proc Am Coll Vet Med* 1995;13:298–299.
- Calvert CA, Jacobs GJ, Smith DD, et al. Association between results of ambulatory electrocardiography and development of cardiomyopathy during long-term follow-up of Doberman Pinschers. *J Am Vet Med Assoc* 2000;216:34–39.
- Bonagura J, Luis Fuentes V. Echocardiography. In: Ettinger SJ, Feldman EC, eds. *Textbook of Veterinary Internal Medicine*, 5th ed. Philadelphia, PA: WB Saunders; 2000:834–873.
- Basso C, Fox PR, Meurs KM, et al. Arrhythmogenic right ventricular cardiomyopathy causing sudden cardiac death in boxer dogs. *Circulation* 2004;109:1180–1185.
- Everett RM, McGann J, Wimberly HC, et al. Dilated cardiomyopathy of Doberman Pinschers: Retrospective histomorphologic evaluation of heart from 32 cases. *Vet Pathol* 1999;36:221–227.
- Ortiz-Lopez R, Schultz KR, Towbin J. Genetic aspects of dilated cardiomyopathy. *Prog Pediatr Cardiol* 1996;2:71–82.
- Meurs KM, Kittleson MD, Spangler E, et al. Nine polymorphisms within the head and hinge region of the feline cardiac beta myosin heavy chain gene. *Anim Genet* 2000;31:231.
- Guyon R, Lorentzen TD, Hitte C, et al. A1-Mb resolution radiation hybrid map of the canine genome. *Proc Natl Acad Science* 2003;100:5296–5301.
- Cargill EJ, Clark LA, Steiner JM, et al. Multiplexing of canine microsatellite markers for whole-genome screens. *Genomics* 2003;80:250–253.
- Terwilliger J, Ott J. Running the LINKAGE programs MLINK and ILINK. In: *Handbook of Human Genetic Linkage*. Baltimore, MD: The Johns Hopkins University Press; 1994:22–32.
- Liu SK, Fox PR. Cardiovascular pathology. In: Fox PR, Sisson DD, Moise NS, eds. *Textbook of Canine and Feline Cardiology*, 2nd ed. Philadelphia, PA: WB Saunders; 1999:817–844.
- Bachinski LL, Roberts R. New insights into dilated cardiomyopathy. *Cardiol Clin* 1998;16:603–610.
- Arbustini E, Morbini P, Pilotto A, et al. *Herz* 2000;25:156–160.
- Ostrander EA, Giniger E. Semper fidelis: What man's best friend can teach us about human biology and disease. *Am J Hum Genet* 1997;61:475–480.
- Walker J. *New Doberman Pinscher*. Hoboken, NJ: Howell Book House; 1981:18–25.
- Whitney JC. Observations on the effect of age on the severity of heart valve lesions in the dog. *J Small Anim Pract* 1974;15:511–522.
- Dukes-McEwan J. The promises and problems of linkage analysis by using the current canine genome map. *Mamm Genome* 2002;13:667–672.
- Burkett EL, Hershberger RE. Clinical and genetic issues in familial dilated cardiomyopathy. *J Am Coll Cardiol* 2005;45:969–981.
- Stabej P, Imholz S, Versteeg SA, et al. Characterization of the canine desmin gene and evaluation as a candidate gene for dilated cardiomyopathy in the Doberman. *Gene* 2004;340:241–249.
- Stabej P, Leegwater PA, Imholz S, et al. The canine sarcoglycan delta gene: BAC clone contig assembly, chromosome assignment and interrogation as a candidate gene for dilated cardiomyopathy in Doberman dogs. *Cytogenet Genome Res* 2005;111:140–146.
- Stabej P, Leegwater PA, Stokhof AA, et al. Evaluation of the phospholamban gene in purebred large-breed dogs with dilated cardiomyopathy. *Am J Vet Res* 2005;66:432–436.
- Meurs KM, Magnon AL, Spier AW, et al. Evaluation of the cardiac actin gene in Doberman Pinschers with dilated cardiomyopathy. *Am J Vet Res* 2001;62:33–36.